

INTRODUCTION

Periapical pathology is one of the most commonly occurring findings in dentistry¹. The proper diagnosis of lesions identified in the periapical region is of utmost importance when determining proper course of treatment. Often, radiolucent lesions discovered at the apex of teeth are prematurely classified as lesions of pulpal or periodontal origin. Early signs of systemic diseases such as cancer and rarely tuberculosis manifest themselves as periapical lesions in the oral cavity, and early detection and treatment can greatly improve outcomes for patients². This case study highlights the importance of submitting tissues for biopsy in distinguishing periapical lesions of endodontic/periodontal origin from other rare lesions found in this area.

CASE REPORT

A 62 year old male presented to Interfaith Medical Center with a referral from his dentist for extraction of #14. The patient reported throbbing tooth pain (6/10 on pain scale) from the upper left quadrant for the last 3-4 weeks.

- **Intraoral exam:** Tooth #14 M2 mobility and supra-eruption
- **Radiograph:** Periapical radiograph (Fig 1) illustrates a supra-erupted #14 with a somewhat well-defined radiolucency located at the apex of palatal root. Generalized moderate horizontal bone loss and a low sinus floor are also observed.
- **Clinical Diagnosis:** Tooth #14 displays localized severe chronic periodontitis with rarifying osteitis at palatal root apex
- **Differential Diagnoses:**
 1. Periapical cyst - stimulated by the inflammation from periodontal condition (note the absence of caries)
 2. Periapical granuloma - (granulation tissue from the periodontal condition)
 3. Downgrowth of sulcular epithelium in a periodontally compromised tooth
 4. Other rare pathology
- **Treatment:** Extraction #14 and submission of periapical tissue in 10% formalin to pathology lab for histopathologic examination

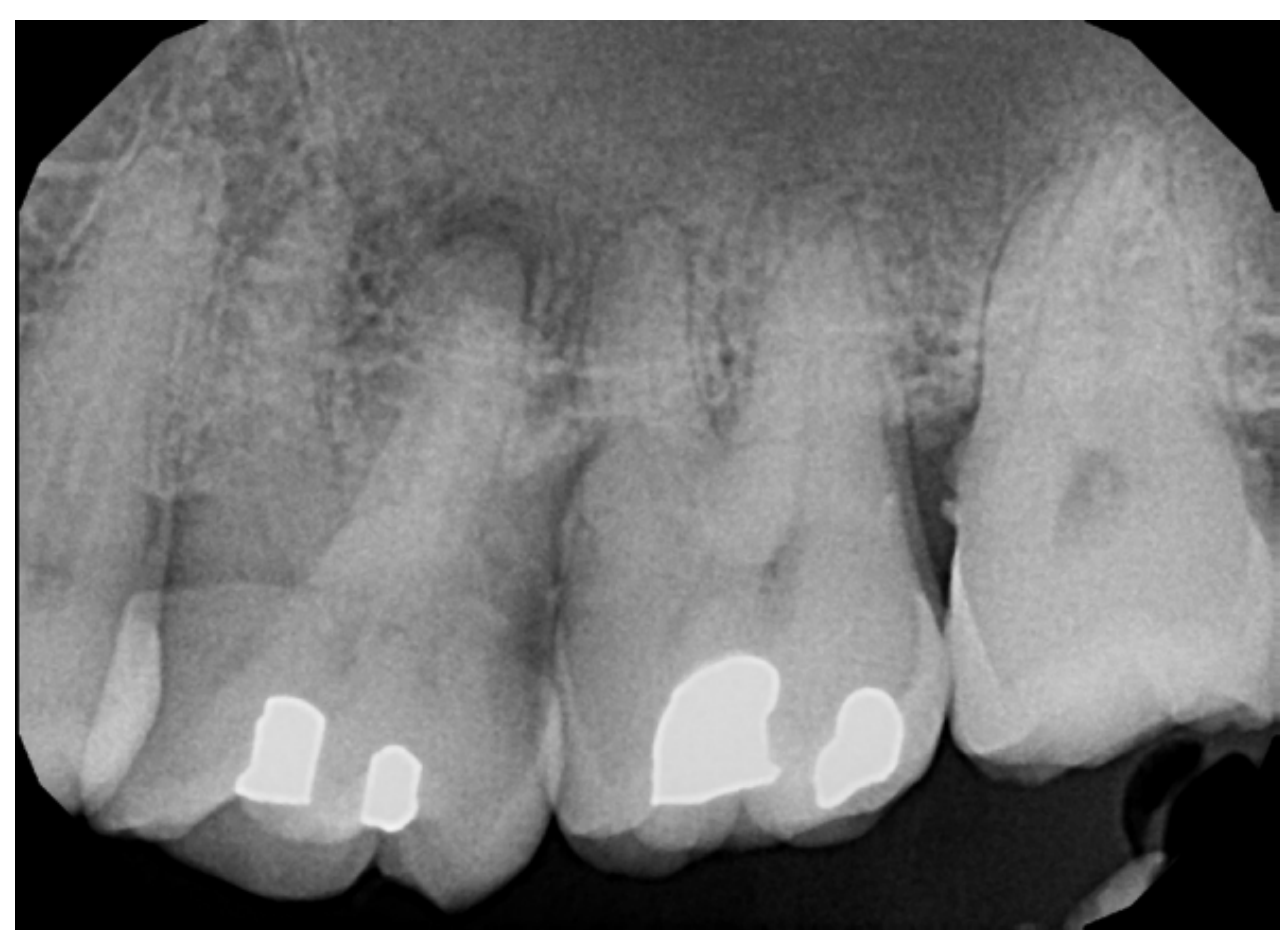

Figure 1: Periapical xray reveals loss of PDL at apex of palatal root of #14 and generalized moderate horizontal bone loss in the upper left quadrant.

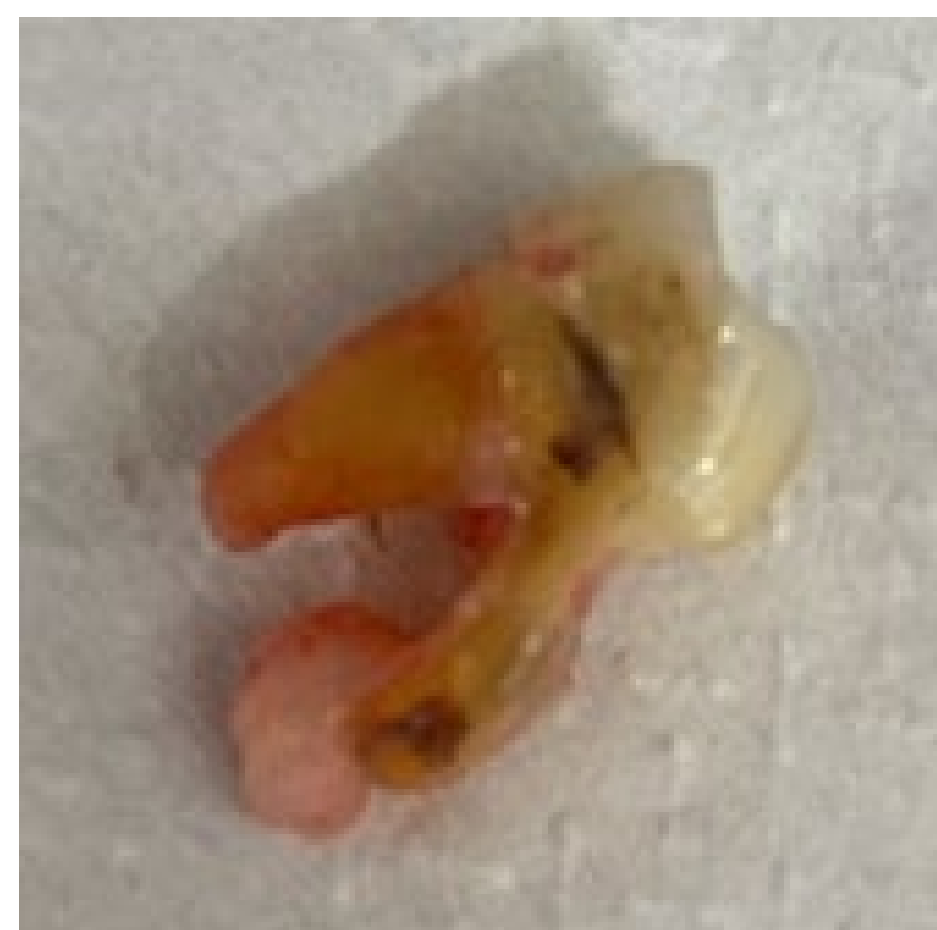

Figure 2: Extracted #14 and periapical tissues attached to the apex of palatal root

BIOPSY RESULTS

Final Diagnosis (Fig 3):

“Epithelial-lined inflamed fibrous connective tissue consistent with periapical cyst or downgrowth of sulcular epithelium”

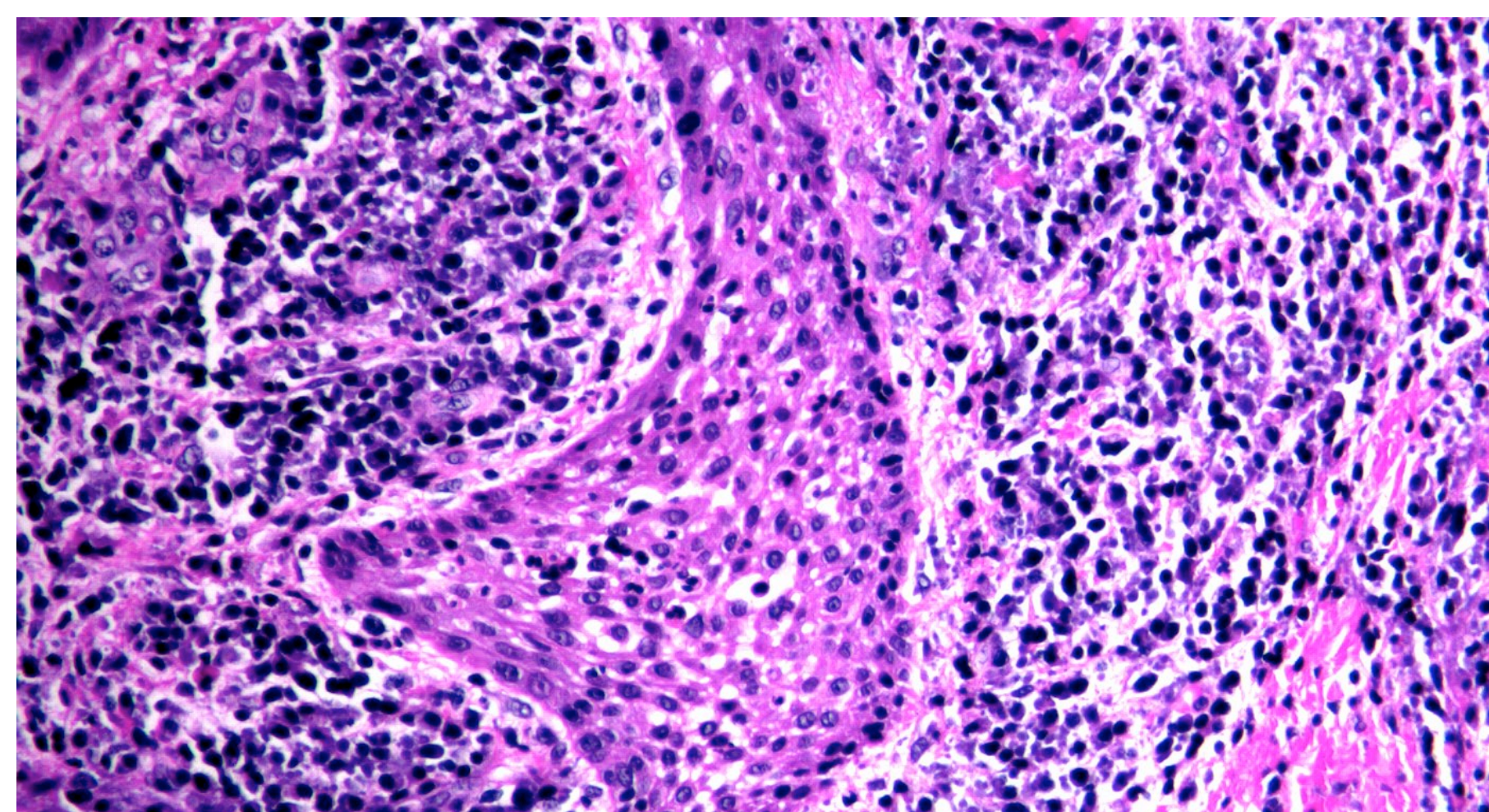


Figure 3: High power histopathology slide showing stratified squamous epithelium (center) with surrounding chronic inflammation composed of lymphocytes and plasma cells in a well-vascularized stroma.

DISCUSSION

The previous case report is one of 50 total periapical lesions which were biopsied at Interfaith Medical Center from June 2017 to March 16th 2021. Biopsy reports were reviewed, and the results are summarized in the chart below (Table 1). Out of 50 biopsies in total, one was diagnosed as a central giant cell granuloma.

Final Diagnosis	# of Patients	Percentage of Total Periapical Tissue Biopsies
PA Cyst	38	76%
PA Granuloma	11	22%
Central Giant Cell Granuloma	1	2%
Total	50	100%

Table 1: Chart summarizing biopsy results from periapical lesions submitted for histopathologic diagnosis during extractions performed at IMC from June 2017-March 2021

- Biopsy reports of periapical lesions do not always reflect a differential diagnosis
- Always submit periapical tissues to obtain a correct diagnosis
- Kontogiannis et al.¹ reviewed 1521 biopsies of periapical tissues over 14 years to determine incidence of lesions that are not pulpal in origin, despite their clinical diagnosis of:
 - ‘periapical inflammation’
 - ‘periapical abscess’
 - ‘periapical granuloma’
 - ‘periapical cyst’
- In ~3% of cases, histological diagnosis is not consistent with lesions of pulpal origin
- Many unique lesions may mimic inflammatory pulpal pathology and subsequently be undiagnosed:
 - Odontogenic keratocysts (OKC) are the most common lesion (33% of cases)³
 - Fibro-osseous lesions are the second most common²
 - Less common lesions: glandular odontogenic cysts, lateral periodontal cysts, central ossifying fibromas and malignancies (metastatic carcinomas from lung/breast tissues and Langerhans cell histiocytosis)

Oral and maxillofacial surgeons are trained to submit all tissue removed from the oral cavity for examination. The importance of submitting tissues for histopathologic examination should be emphasized to any professional who routinely removes tissue from the body.

CONCLUSION

All periapical lesions are not histopathologically diagnosed as cysts and granulomas of inflammatory origin. It is important to submit all tissues to correctly diagnose periapical lesions in order to properly manage patients and provide optimal healthcare.

REFERENCES

1. Kontogiannis TG, Tosios KI, Kerezoudis NP, Krithinakis S, Christopoulos P, Sklavounou A. Periapical lesions are not always a sequelae of pulpal necrosis: a retrospective study of 1521 biopsies. *Int Endod J.* 2015 Jan;48(1):68-73. doi: 10.1111/iej.12276. Epub 2014 Apr 2. PMID: 24579658.
2. Xia, Wen-wei et al. “Six cases report of differential diagnosis of periapical diseases.” *International journal of oral science* vol. 3,3 (2011): 153-9. doi:10.4248/IJOS11055
3. Ali M, Baughman RA. Maxillary odontogenic keratocyst: a common and serious clinical misdiagnosis. *J Am Dent Assoc.* 2003 Jul;134(7):877-83. doi: 10.14219/jada.archive.2003.0286. PMID: 12892445.